

CASE STUDY

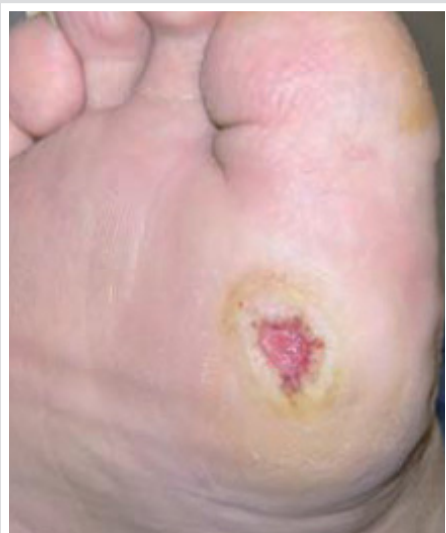Management of a Metatarsal Delayed Union with CERAMENT™|BONE VOID FILLER

JEFFREY C. KARR DPM

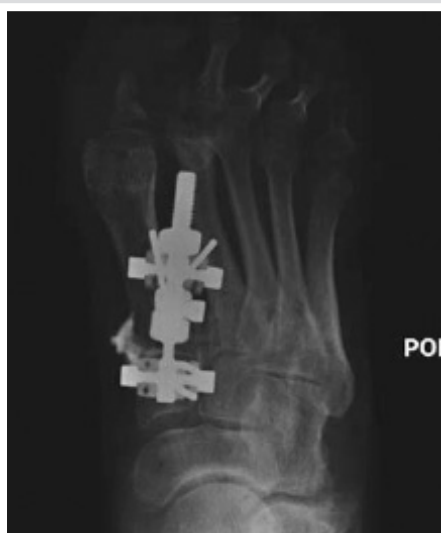Lakeland Regional Medical Center , Lakeland , Florida , U.S.A.

(Address for correspondence , 5421 South Florida Avenue, Lakeland, Florida, U.S.A.)

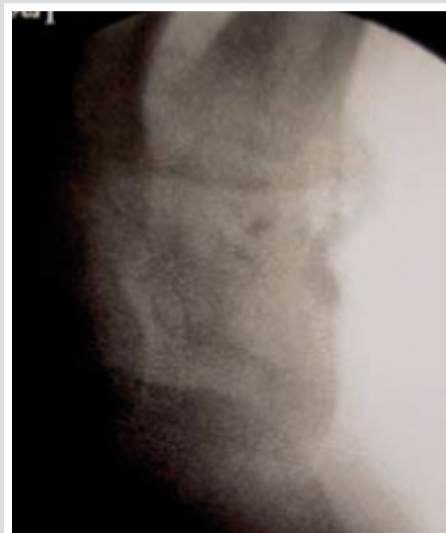
PATIENT	41 Year old male
DIAGNOSIS	<ul style="list-style-type: none"> • Metatarsal delayed union • Conservative treatment unsuccessful (weekly debridement, pressure off-loading, grafting and collagen-based dressings) • Lower extremity arterial circulation had no significant stenotic disease • Medical history significant for type 2 diabetes, hypertension, coronary artery disease with history of MI, chronic renal insufficiency, anemia and obesity • Right chronic diabetic foot ulcer at a prominent first meta tarsal head
TREATMENT	<ul style="list-style-type: none"> • Mid foot fusion with external fixation at the first meta tarsal cuneiform joint to raise/dorsiflex the first metatarsal head decreasing pressure at the diabetic foot ulcer • Ulcer measured 2.0 x 1.0 x 0.5 cms located at the plantar right foot superficial to a prominent first metatarsal head • Delayed healing at 4 weeks post operative • Patient was concerned since he only had few sick days left placing his employment at risk • A bone stimulator was started the following week, after 3 weeks there was no significant bone healing • 2 months post operatively surgical intervention for the percutaneous delivery of CERAMENT™ BONE VOID FILLER at the site of metatarsal delayed union utilizing intra-operative fluoroscopy
OUTCOME	<ul style="list-style-type: none"> • CERAMENT™ strengthened the delayed union site and accelerated osseous healing and union immediately • 5 days post operatively the mini-external fixator was removed and the patient returned to work the following day • At 1 year post operatively the patient was progressing well without incident



Picture 1. Chronic diabetic foot ulcer at a prominent first metatarsal head.



Picture 2. Percutaneous delivery of CERAMENT™ was accomplished at the metatarsal delayed union site



Picture 3. The patient is one year post-operatively and is progressing with out incident.



OUR MISSION is to provide an injectable radiopaque bone substitute that has been proven to rapidly remodel into bone, with the potential to be combined with other substances, and is capable of being delivered percutaneously.

BONESUPPORT AB
Ideon Science Park,
Scheelevägen 19 A
SE-223 70 Lund, Sweden

T: +46 46 286 53 70
F: +46 46 286 53 71
E: info@bonesupport.com

www.bonesupport.com