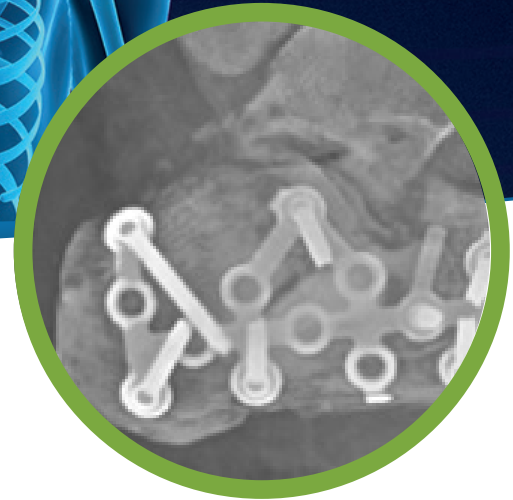
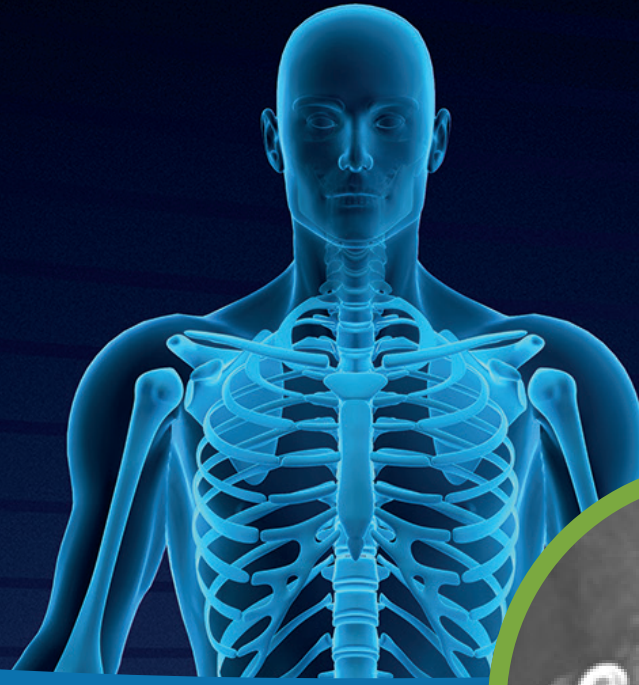


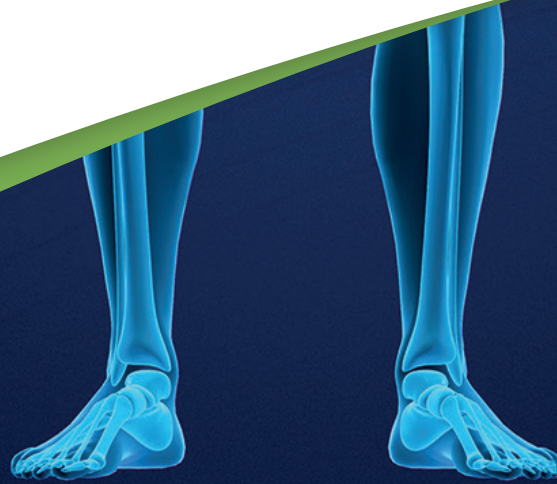Case Report:

Treatment of displaced intra-articular calcaneal fracture with
CERAMENT® | BONE VOID FILLER

Damiano Papadia

Reparto di Ortopedia e, Traumatologia Ospedale, Santa Chiara, Trento, Italy



PATIENT

54 year old female

DIAGNOSIS

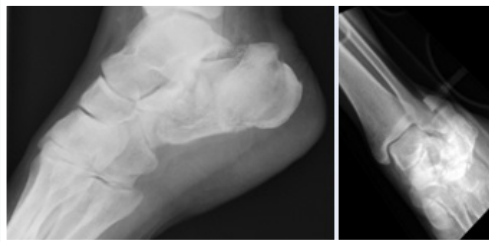
- Displaced intra-articular calcaneal fracture Sanders 4.
- Some authors have reported that filling of bone defects with open reduction and internal fixation (ORIF) of displaced intra-articular calcaneal fractures (DIACF's) is unnecessary.
- However, we have observed reduced calcaneal height of the posterior facet and reduction of Bohler's angle when full weight bearing is allowed at 3 months in patients with significant bone defects after fracture reduction treated with ORIF LCP alone.

TREATMENT

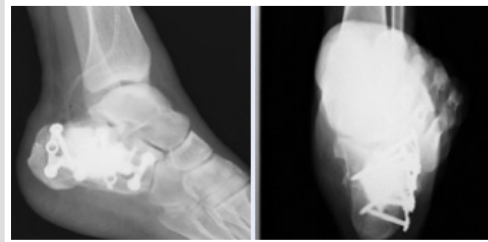
- Open reduction and internal fixation.
- Augmentation with CERAMENT®|BONE VOID FILLER.
- Gradual weight bearing up to 3 months and then full weight bearing.
- Removal of plate after 4 months due to discomfort of the surgical wound with no signs of infection.

OUTCOME

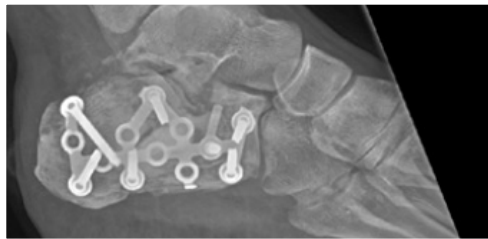- At 7 months patient demonstrated a good result.
- Maryland Foot Clinic Score Clinical Evaluation = 87/100 points.
- CERAMENT®|BONE VOID FILLER is an option for management of DIAF's.
- It enables reconstruction of large bone defects, allows for functional recovery and prevents post operative reduction of calcaneal height of the posterior facet.



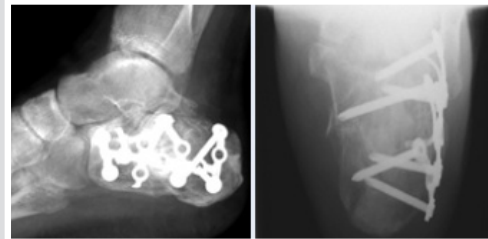Picture 1 & 2. X-ray of fracture.



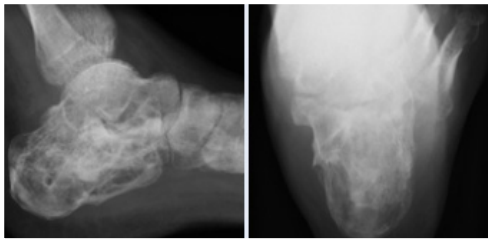
Picture 3 & 4. X-ray immediately post surgery.



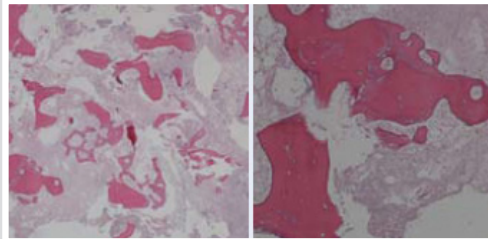
Picture 5. X-ray 30 days post surgery.



Picture 6 & 7. X-ray 45 days post surgery.



Picture 8 & 9. X-ray at 5 months post surgery after removal of plate.



Picture 10 & 11. Histology at 4 months showing new bone growth.



Restoring health to improve the quality of life for patients with bone disorders.

BONESUPPORT, INC.,
60 William St, Suite 330, Wellesley, MA 02481
T: 1.877.719.6718

www.bonesupport.com

PR 0119-04 en US